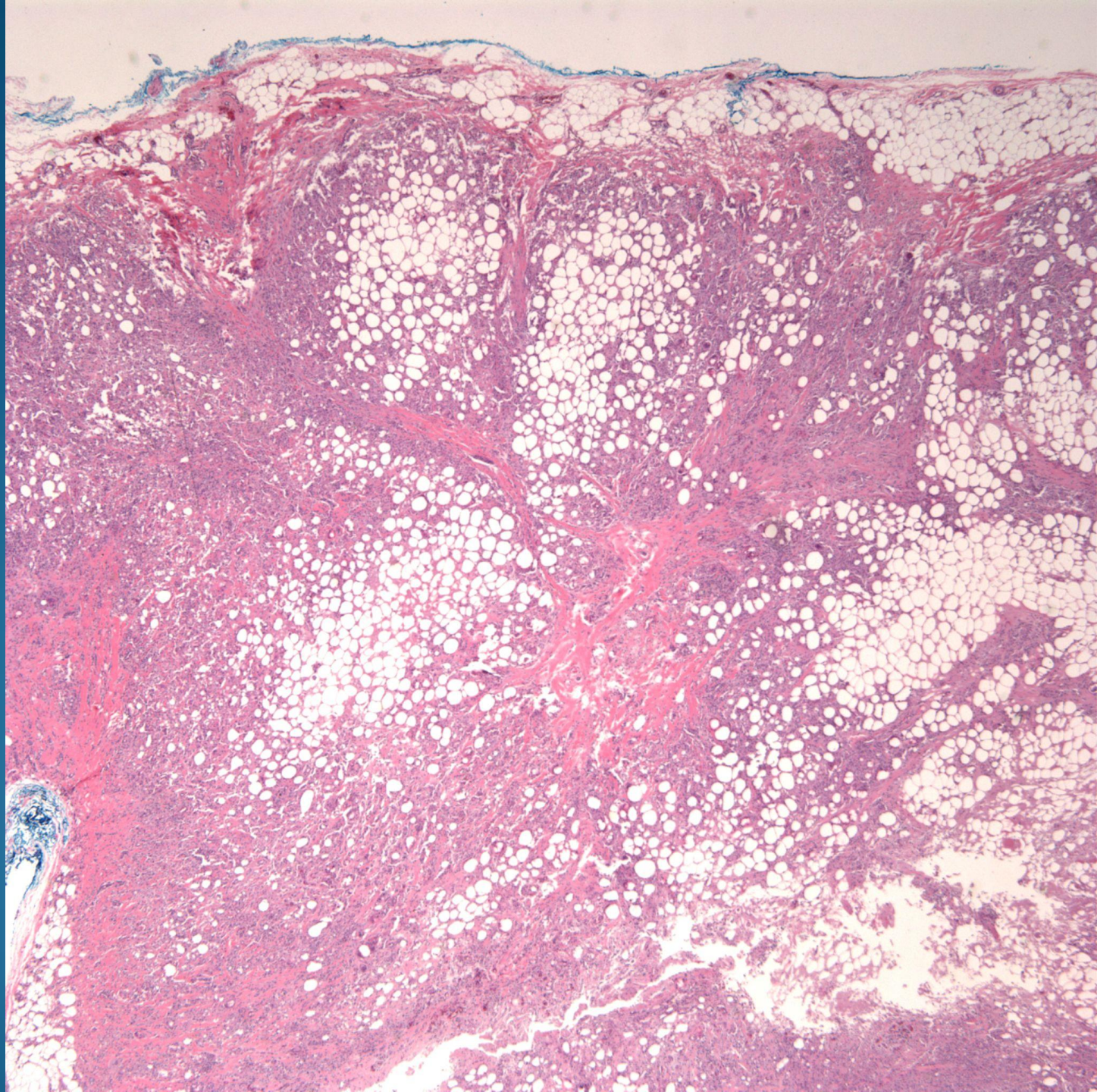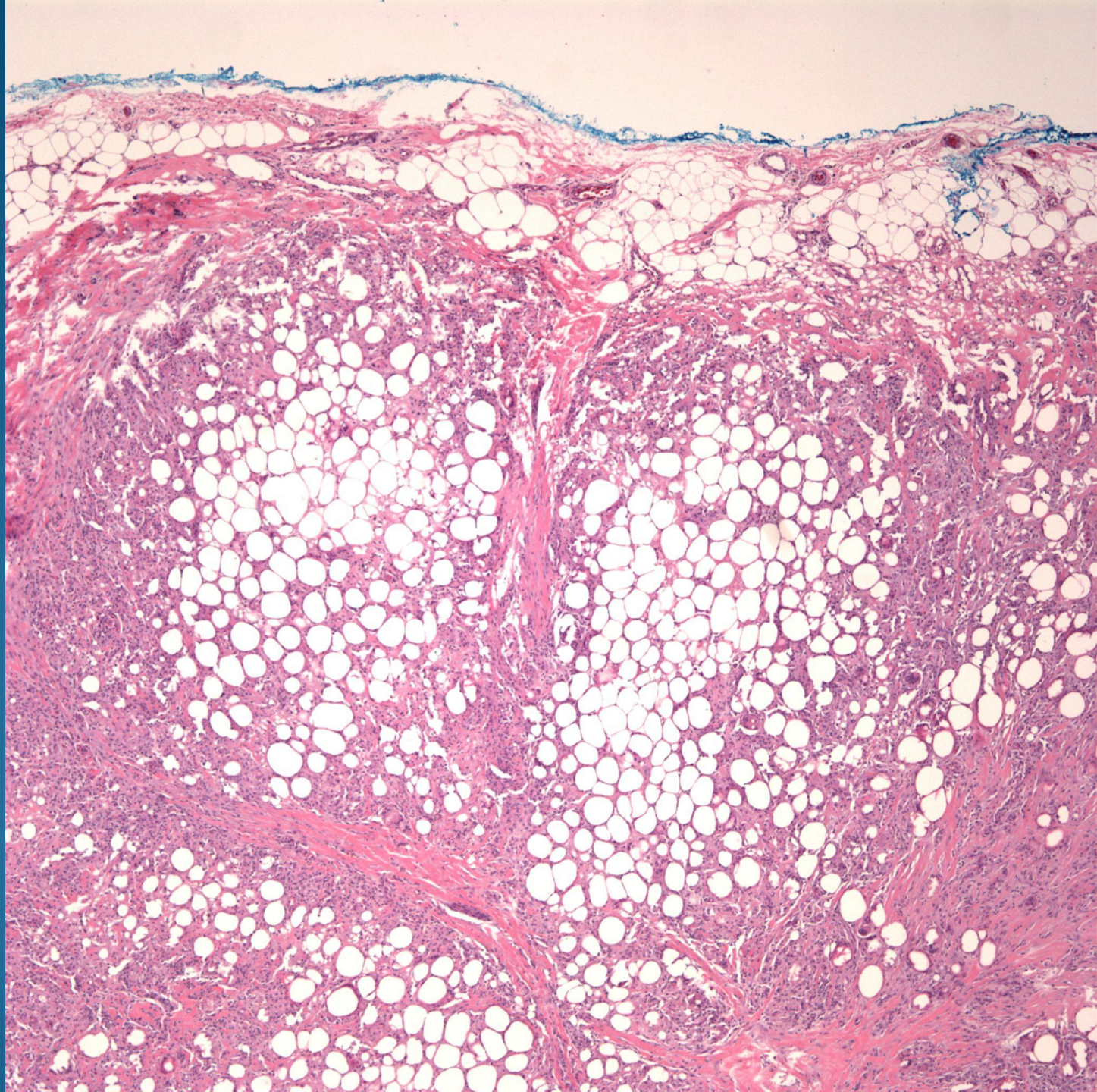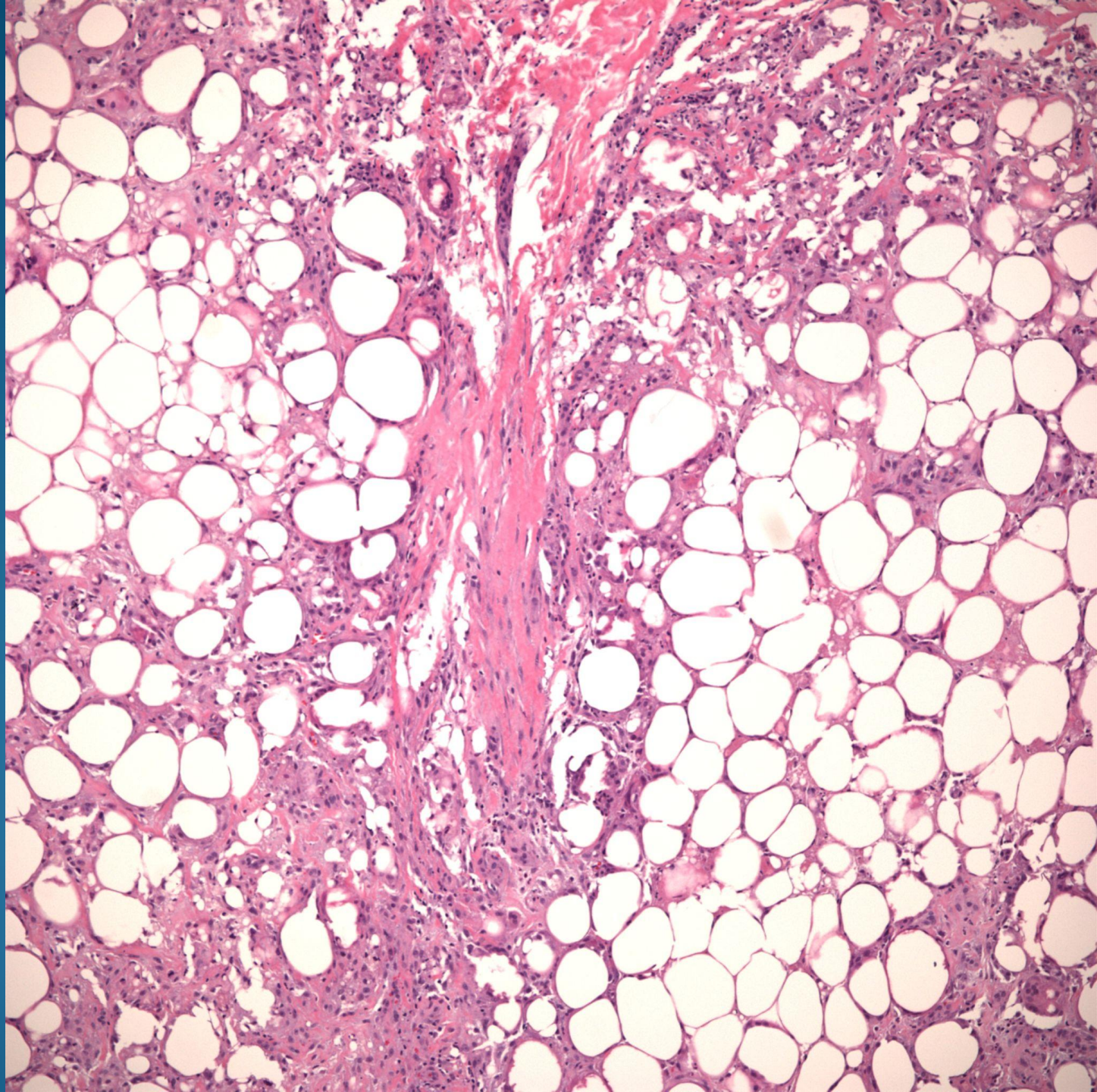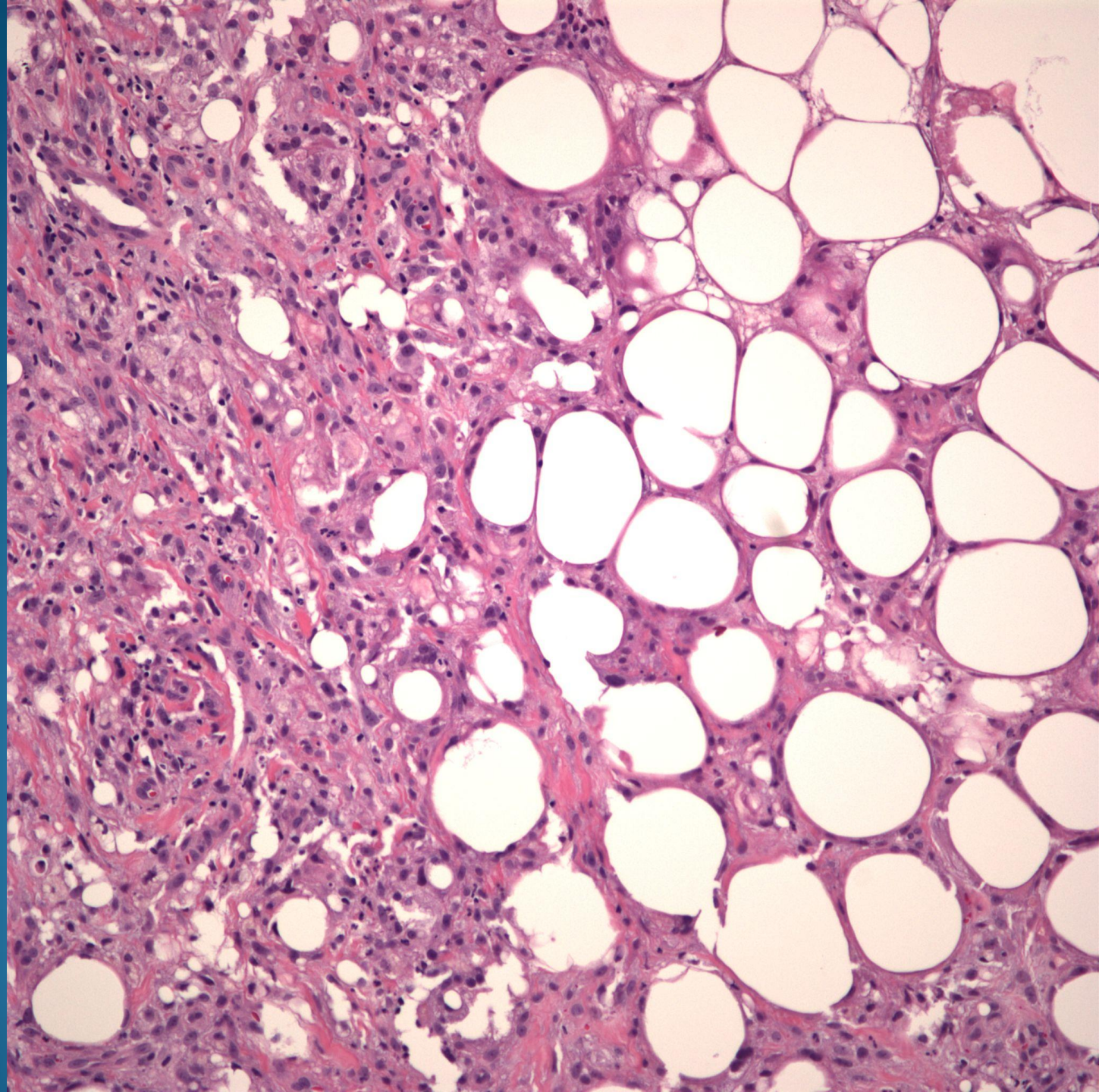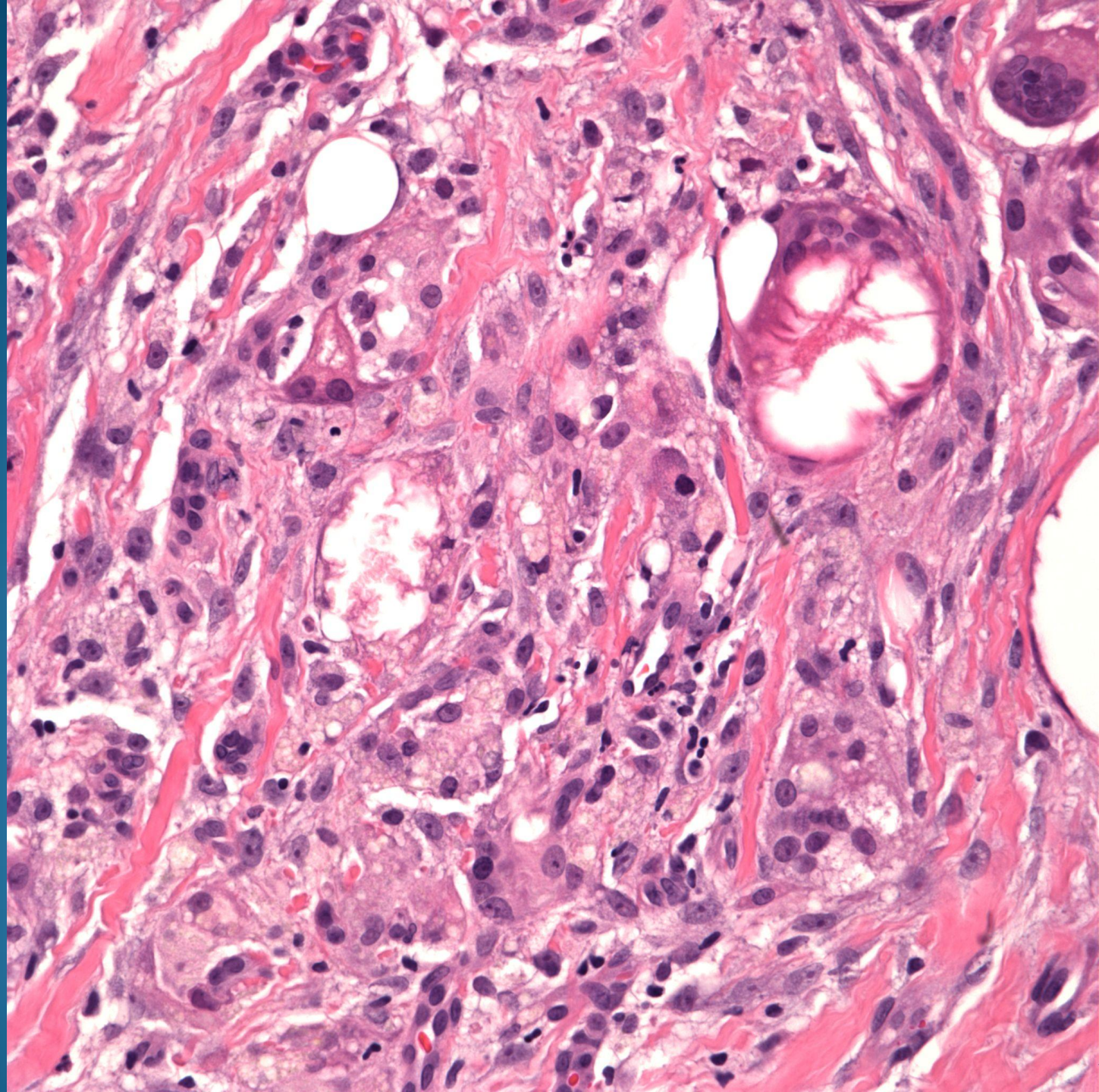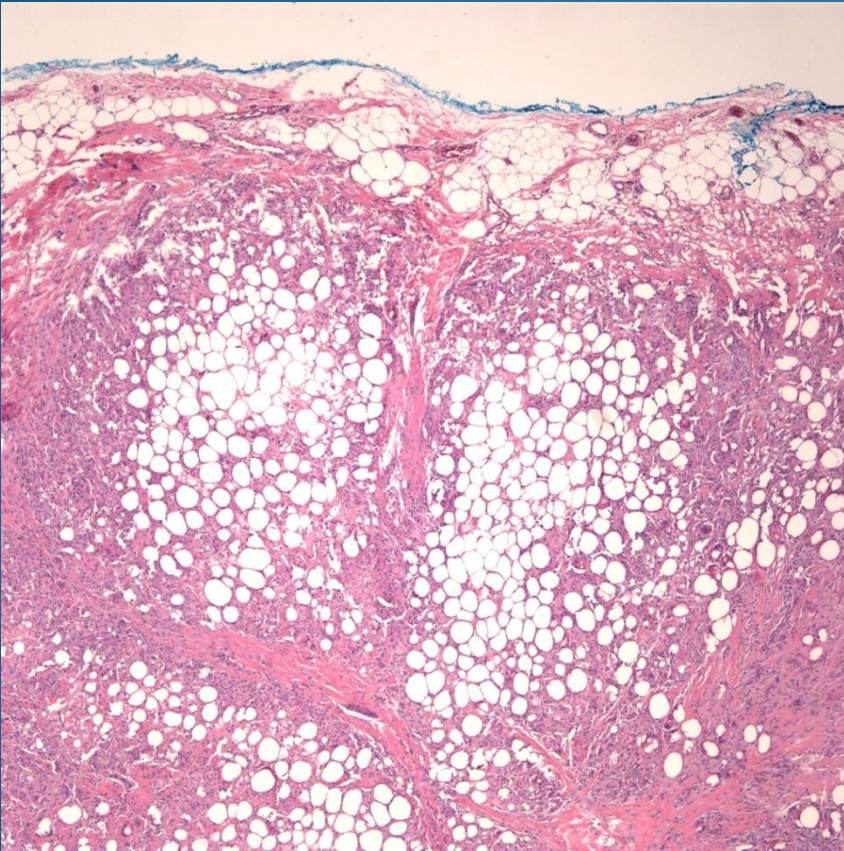


Lipoma with Fat Necrosis

Pearls



- May clinically simulate a malignant neoplasm
- Low power view of a circumscribed collection of mature adipose tissue consistent with lipoma
- Fat necrosis with foreign body giant cell reaction and lipophages